



Deep vein thrombosis with tuberculosis: a rare presentation of common disease

Prasad Muley^{1*}, Urjita Shah², Varsha Shah³, Dulari Gandhi⁴

ABSTRACT

Tuberculosis remains an infectious disease with high prevalence worldwide. An association between tuberculosis-induced inflammation and hypercoagulable state has been described in the literature. Deep vein thrombosis is a rare complication of the disease, and very few cases are reported worldwide. Furthermore, such manifestation is very rare in the paediatric age group. The paediatrician's awareness of this phenomenon is important for early diagnosis and prompt treatment. Here, we report two cases of severe pulmonary tuberculosis associated with deep vein thrombosis in the pediatric age group.

Keywords: DVT, Pulmonary tuberculosis, Paediatric

INTRODUCTION

Tuberculosis (TB) is an infectious disease with high prevalence in India and worldwide. In 2010, the incidence was approximately 8.8 million among HIV-negative people¹. Venous thromboembolism is a rare complication of this disease, and it may be a potentially life-threatening event. Deep vein thrombosis (DVT) is clinically observed and can be confirmed with laboratory methods in patients with pulmonary tuberculosis (PTB). Lack of awareness of this association can prevent the development of standardized screening and treatment strategies. DVT has been reported as a complication of tuberculosis in adults. Here, we report a case series of severe pulmonary tuberculosis associated with DVT in paediatric patients. Our series highlights the occurrence of DVT and associated diagnostic dilemma in patients with severe PTB.

Case 1: A 15-year-old adolescent male reported to emergency with complaints of high-grade fever, painful swelling of both lower limbs for the past 15 days, and breathlessness for the past 4 days. He also had a history of anorexia, weight loss, and abdominal

pain for the last few months. The child was not taking any medication. Past and family history was insignificant. Also, history of Koch's contact was absent. On admission, he had fever (38.3°C), tachycardia at 102 bpm, tachypnoea at 56/min, BP (110/68 mm Hg), and SpO₂ 0.85 in room air. On general examination, the child had edema (rt > lt) and tenderness on both lower limbs. Chest auscultation revealed extensive bilateral crepitations. The remainder of the systemic examination was normal.

Laboratory investigation revealed leucocytosis (17.6×10⁹/L), anaemia level measured at (Hb-92 gm/L), thrombocytopenia (79×10⁹/L), and ESR- 80 at the end of 1 hr. Mantoux test was positive (14mm). Renal function, liver function, prothrombin time, and activated partial thromboplastin time were normal.

GJMEDPH 2014; Vol. 3, issue 1

² Pediatric Resident, Dept.

Pediatrics

S.B.K.S MIRC, Sumandeep
Vidyapeeth

³ Associate Prof., Dept. Pediatrics

S.B.K.S MIRC, Sumandeep
Vidyapeeth

⁴ Professor & Head, Dept.

Pediatrics

S.B.K.S MIRC, Sumandeep
Vidyapeeth

*Corresponding author

¹ Prasad Muley

Professor, Dept. Pediatrics

S.B.K.S. MIRC, Sumandeep

Vidyapeeth, at Po Piparia, Ta

Waghodia, Vadodara - 391760

Gujarat, India

muleyprasad@yahoo.com

Conflict of Interest—none

Funding—none

Direct coomb's test, rheumatoid factor, antiphospholipid antibody, antineutrophilic antibody, and antibodies for HIV by ELISA were negative. Sputum examination was negative for tubercular bacilli.

Chest X-ray and CT chest (**Figure 1**) demonstrated extensive bilateral infiltrations and multiple cavitary lesions with right-sided minimal pleural effusion. ECG and 2D Echo were normal. Ultra Sonography (USG) of the abdomen revealed hepatomegaly and paraaortic lymphadenopathy. Bilateral DVT of the common femoral vein was confirmed by doppler with thrombus on right larger than on the left. USG-guided pleural fluid aspirate showed hemorrhagic exudate with protein 5.2 g/dL, sugar 78mg/dL, TLC $0.5 \times 10^9/L$ with 70% lymphocytes, and Adenosine Deaminase (ADA) was positive (80 U/L).

On the basis of above findings, diagnosis of tuberculosis was made with primary involvement of deep veins of the lower limb. Anti Koch's Treatment (AKT), including rifampicin, isoniazid, ethambutol and pyrazinamide with steroid, was started. Warfarin was started to maintain INR 1.8-2.8. The patient responded to treatment and showed both clinical and radiological improvement. Follow-up at 8 months was uneventful.

Case 2: A 13-year-old male reported with complaints of high-grade fever and acute onset breathlessness for the past six days with no significant family history.

He was moderately built with heart rate-110/min, respiratory rate - 62/min, and SpO₂ 0.83 in room air. He had pallor and extensive bilateral crepitations with intercostal retraction. The remainder of the systemic examination was normal. As in the 1st case. the remaining blood investigations were normal and Mantoux test was negative. CXR was suggestive of multiple bilateral infiltrates with left-sided minimal pleural effusion (**Figure 2**).

Two days after admission, he developed right lower limb swelling and tenderness. Doppler study revealed 3cm x 1cm thrombus on medial aspect of right femoral vein. USG-guided pleural fluid aspirate was hemorrhagic with pH 7, protein 8.4gm/dL, sugar 66 mg/dL, Lactate dehydrogenase 707 IU/L, ADA 98U/L. TLC was $1 \times 10^9/L$ cells with 60% lymphocytes and no organism isolated with Gram or Zeal staining of fluid.

Broad-spectrum antibiotics and IV Heparin were started, but the child did not show any improvement in subsequent seven days. On the basis of X-ray findings, AKT was started. The child improved and was discharged on AKT and warfarin. After 2 months, chest X-ray showed significant improvement. Repeat Doppler also showed regression in the size of thrombus. On follow-up, the child developed limping gait and pain on right hip joint. Hip MRI revealed tuberculosis of right hip joint (**Figure 3**). Patient showed improvement during follow-up period and completely recovered with completion of a six-month course of AKT (standard regimen Category I).

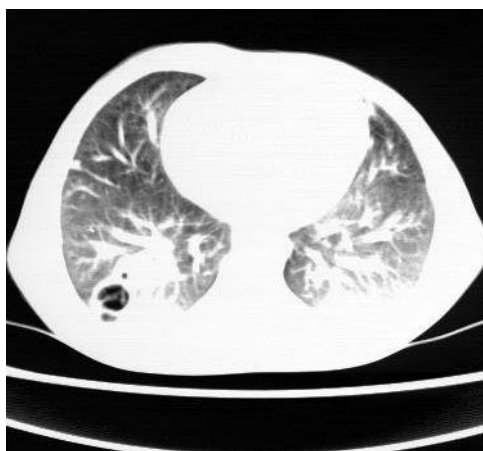


Figure 1 CT scan shows cavity in right lung (Case 1)

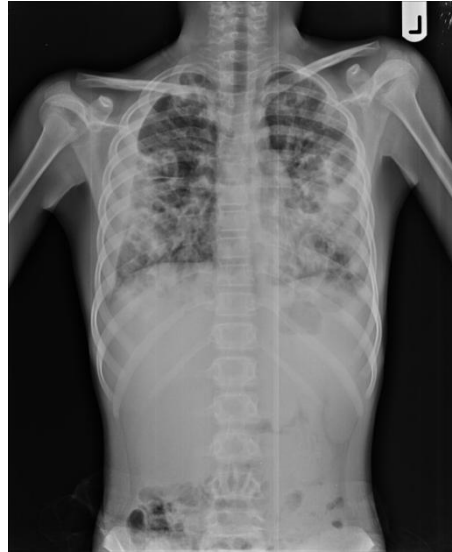

Figure 2 Chest X ray prior to treatment (case 2)

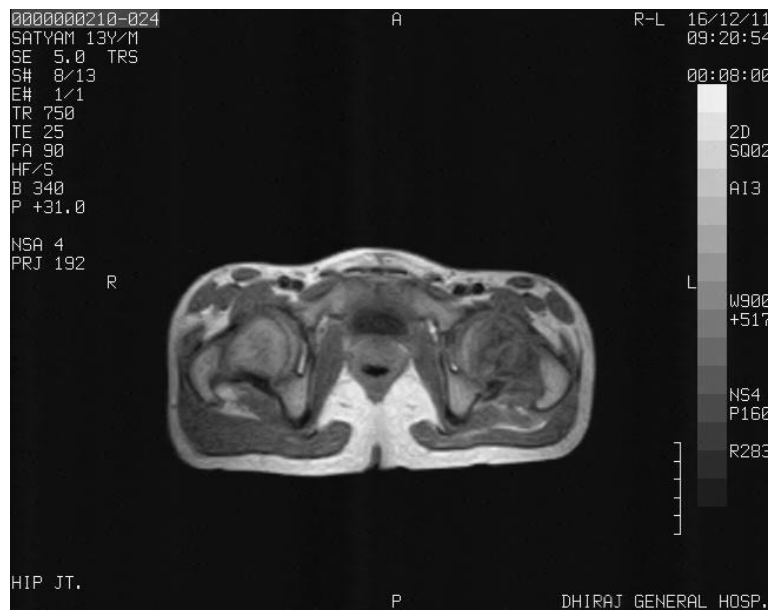


Figure 3 MRI hip suggestive of tuberculosis (case 2)

DISCUSSION

Causes of DVT include prolonged bed rest, long air journeys, cardiac failure, malignant pelvic masses, injury to pelvic veins due to trauma, pelvic surgery, childbirth, hereditary thrombophilia (factor V Leiden defect, protein C, protein S and antithrombin III deficiency states), dysfibrinogenaemia, and acquired thrombophilias found in systemic lupus erythematosus and antiphospholipid syndrome.

DVT with TB is not well known. It has been postulated that interaction between mycobacterial products and the monocytemacrophage system synthesizes large amounts of TNF- α and interleukin-6, which change the normally non-thrombogenic internal surface of the vessel into a thrombogenic surface with subsequent development of local thrombosis².

Our case series shows acute development of venous thrombosis in patients of pulmonary Koch's. The first case presented with signs and symptoms of venous thrombosis followed by respiratory symptoms. Meanwhile, the second case demonstrated the reverse course of symptom development. In a study of 35 pulmonary TB patients with DVT, Robson et al. reported only two cases, in which DVT was the presenting feature³. There are isolated reports of venous thrombosis occurring in unusual sites, such as the inferior vena cava and portal vein in patients of disseminated tuberculosis^{4,5}.

Elevated plasma fibrinogen and impaired fibrinolysis coupled with decreased levels of antithrombin III and reactive thrombocytosis appear to favour the development of DVT in pulmonary Koch's patients³.

Turken et al. found that tuberculosis causes a hypercoagulable state⁶. He also stated that these changes improved with AKT within 4 weeks⁶. Apart from this treatment course, the use of anticoagulant therapy in such patients is also of concern due to the interaction of antitubercular medicine with warfarin. In our cases, the presentation was acute and without prolonged symptoms or immobility. In both cases, tuberculosis could be suspected only by chest X-ray and biochemical examination of the pleural fluid.

We present this case as a rare presentation to highlight that Koch's can be kept in mind as a possibility in case of DVT. At the same time, there is a strong need to standardize the management of such conditions.

REFERENCES

1. World Health Organization. Report on the tuberculosis epidemic, World Health Organization, 2011; WHO/HTM/TB/2011.16.
2. T Ogawa, H Uchida, Y Kusumoto, Y Mori, Y Yamamura, S Hamada. Increase in tumor necrosis factor alpha and interleukin-6-secreting cells in peripheral blood mononuclear cells from subjects infected with Mycobacterium tuberculosis. *Infect Immun* 1991 september;59(9):3021-25.
3. Robson SC, White NW, Aronson I, et.al Acute phase response and the hypercoagulable state in pulmonary tuberculosis. *Br J Haematol* 1996; 93:943-9.
4. Gogna A, Grover S, Arun A, Saluja S. Isolated hepatic inferior vena cava thrombosis in a case of tuberculosis- case report. *JACM*. 2004;5(3):266-8.
5. Júnior JA, Felício A, Fukujima M, et al. An uncommon cause of cerebral venous thrombosis. *Arq Neuropsiquiatr* 2005;63(3-B):852-4.
6. Turken O, Kunter E, Sezer M, et al. Hemostatic changes in active pulmonary tuberculosis. *Int J Tuberc Lung Dis*. 2002;6:927-32.